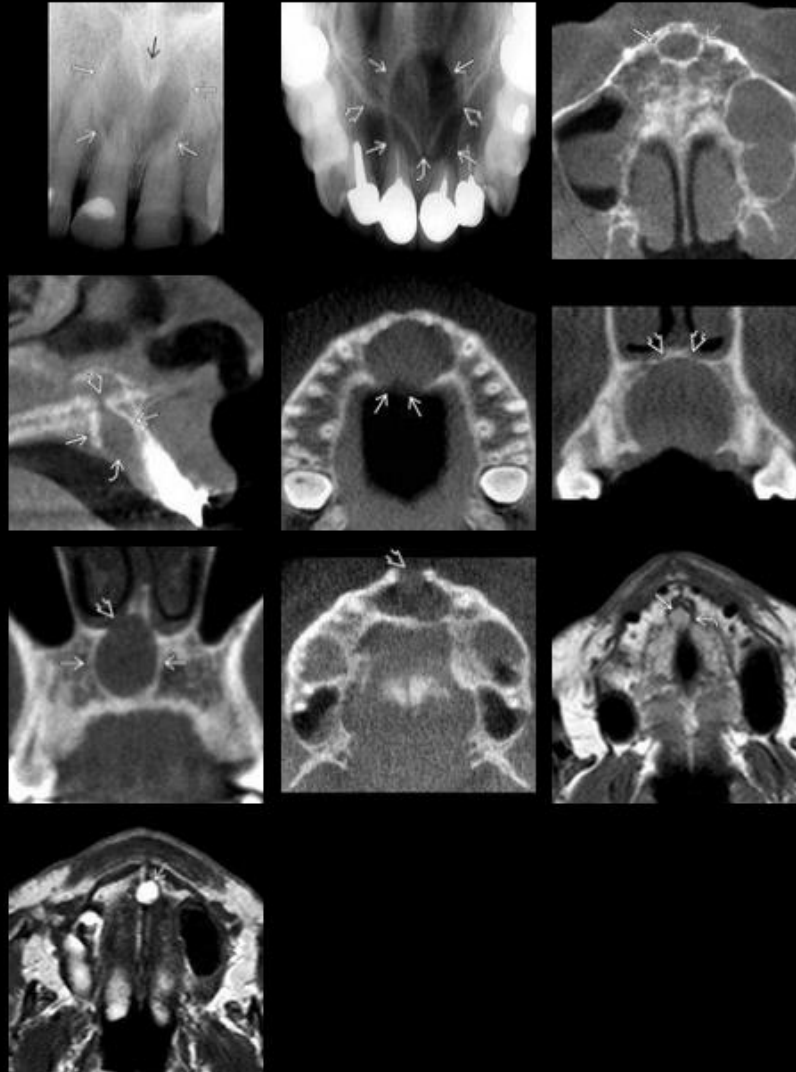


Nasopalatine Duct Cyst



Nasopalatine Duct Cyst

- **Incisive canal cysts**
- Well-defined round or oval radiolucency (> 1 cm) between roots of maxillary central incisors
- Larger lesions may appear "**heart-shaped**" due to superimposition of anterior nasal spine
- Most common nonodontogenic cyst

