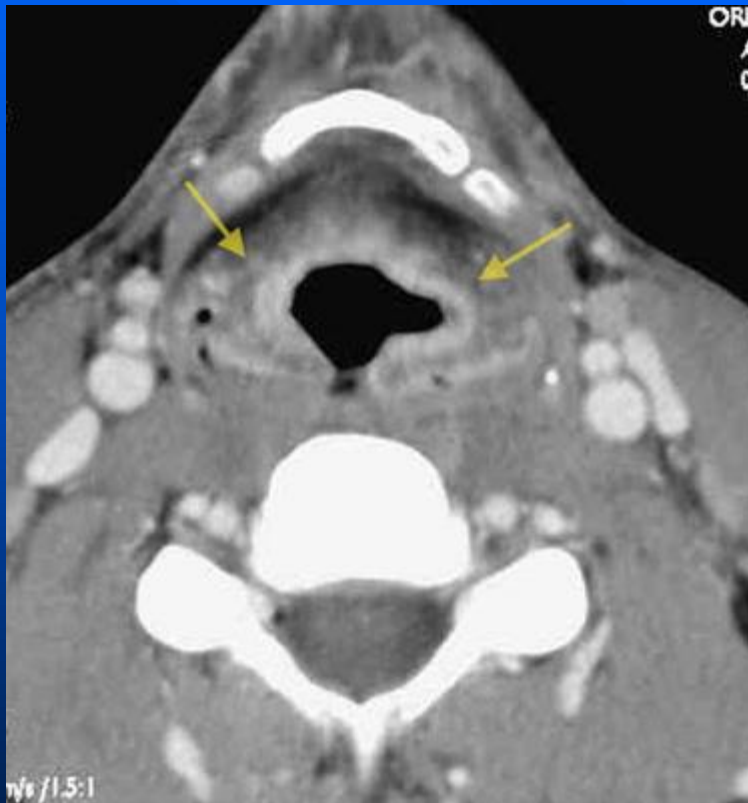
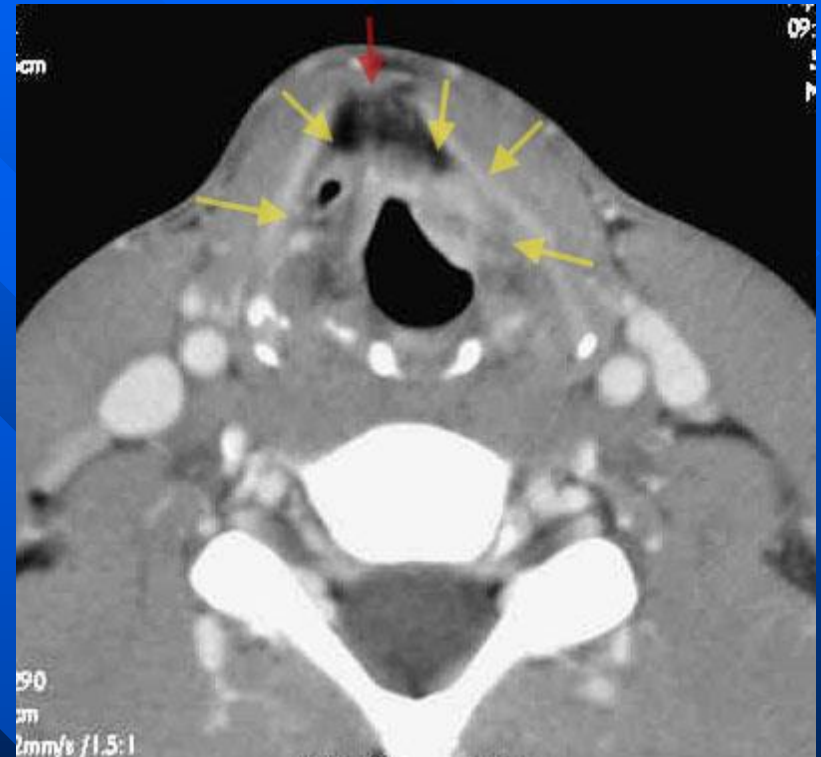
Laryngeal tuberculosis

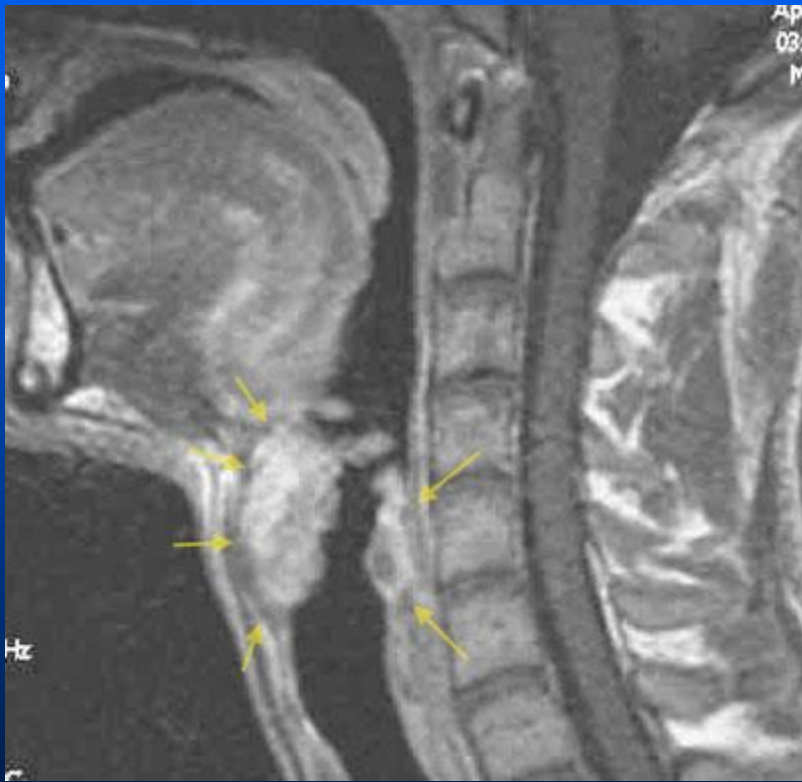


Diffuse, symmetric and bilateral enhancement of aryepiglottic folds



Diffuse, symmetric and bilateral enhancement of False folds

Laryngeal tuberculosis



Laryngeal tuberculosis

- Laryngeal invasion represent a serious complication of pulmonary tuberculosis.
- supraglottic larynx is the most prevalent site of involvement
- most common site is the aryepiglottic fold
- most important differential diagnosis is
 - primary laryngeal carcinoma, where the lesion is usually unilateral associated with an infiltration of preepiglottic and paralaryngeal fat spaces and cartilages destruction. Other diagnosis can be evoked : sarcoidis, syphilis, fungal diseases, chronic nonspecific laryngitis, and lethal midline granuloma.