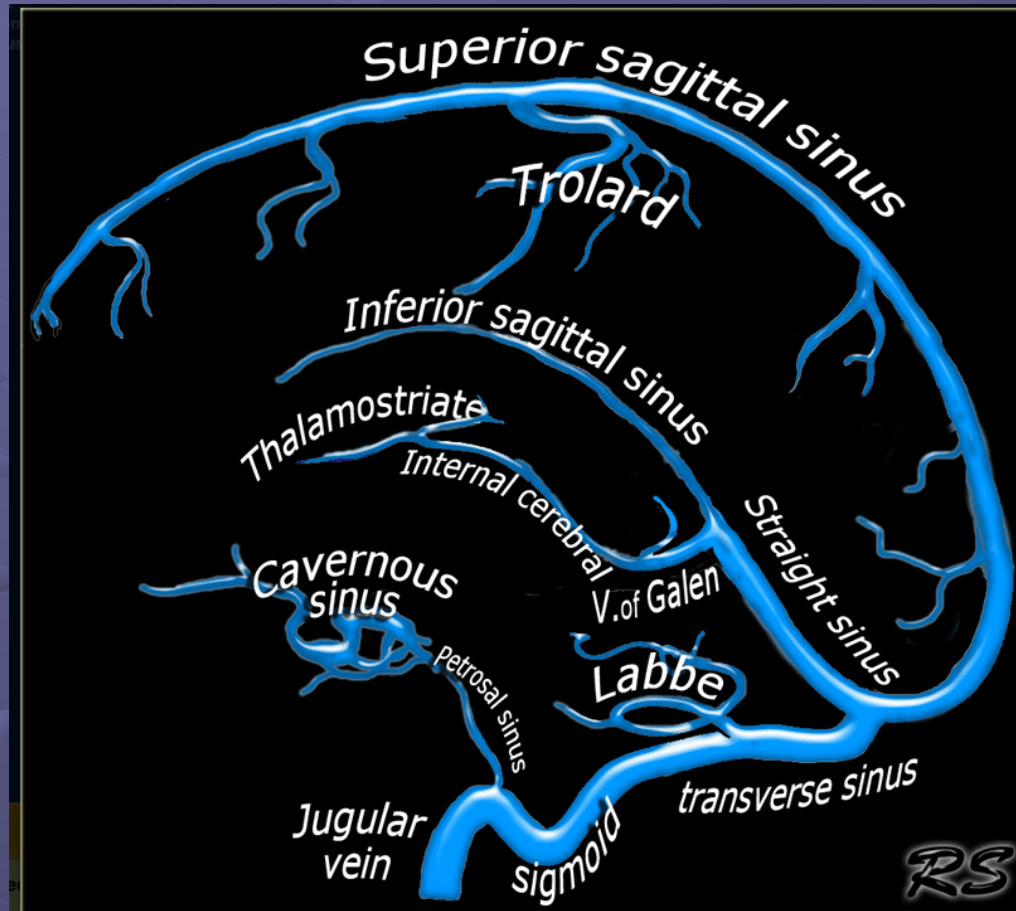


Venous Anatomy

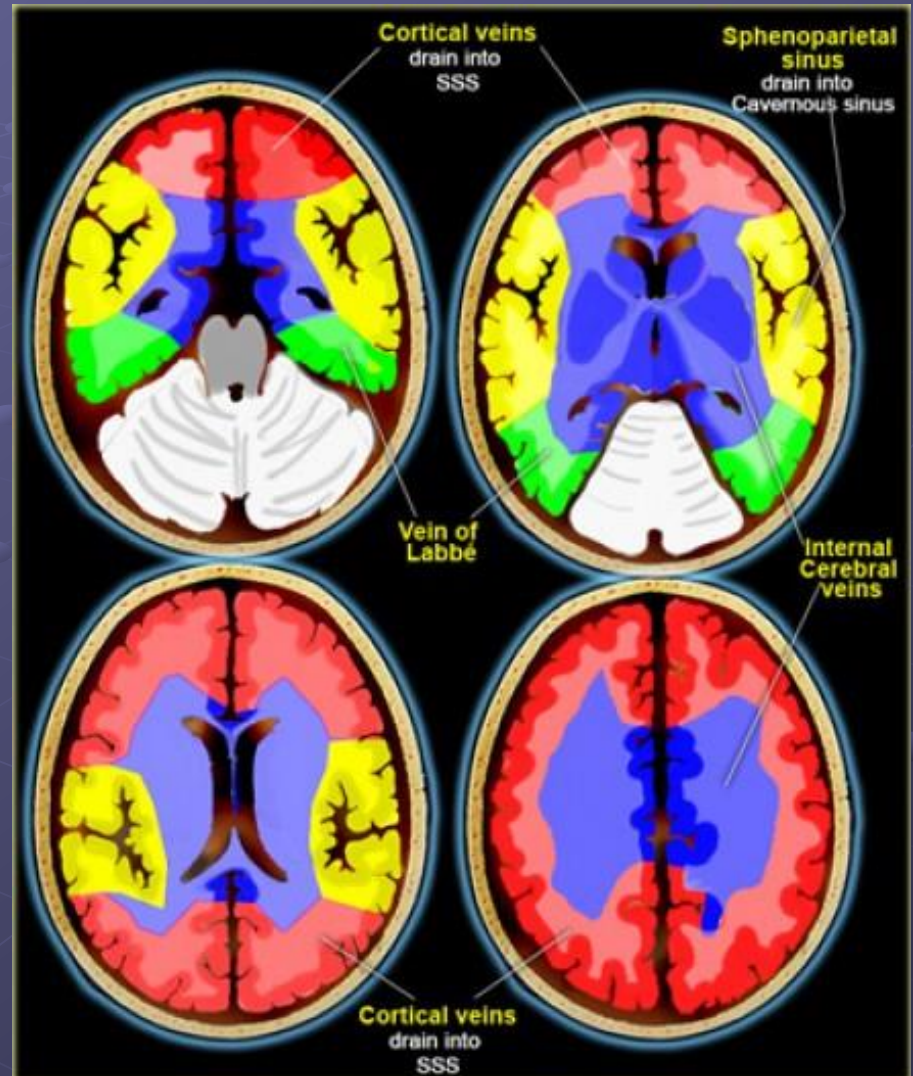


CT Venography

- 45-50 seconds delay after the start of contrast injection.
- We use at least 70 cc of contrast.

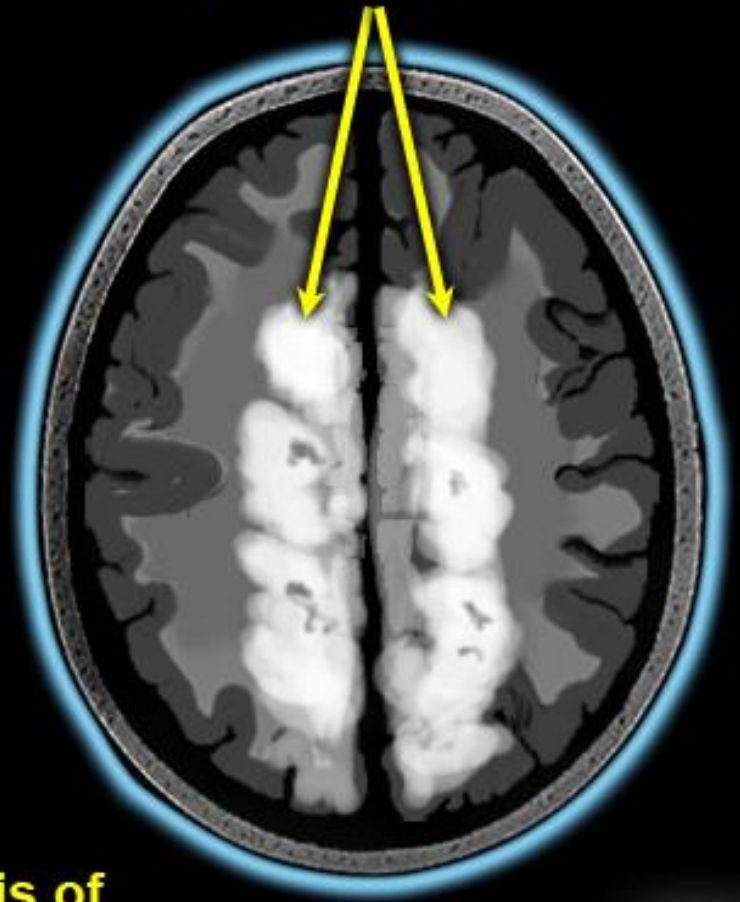
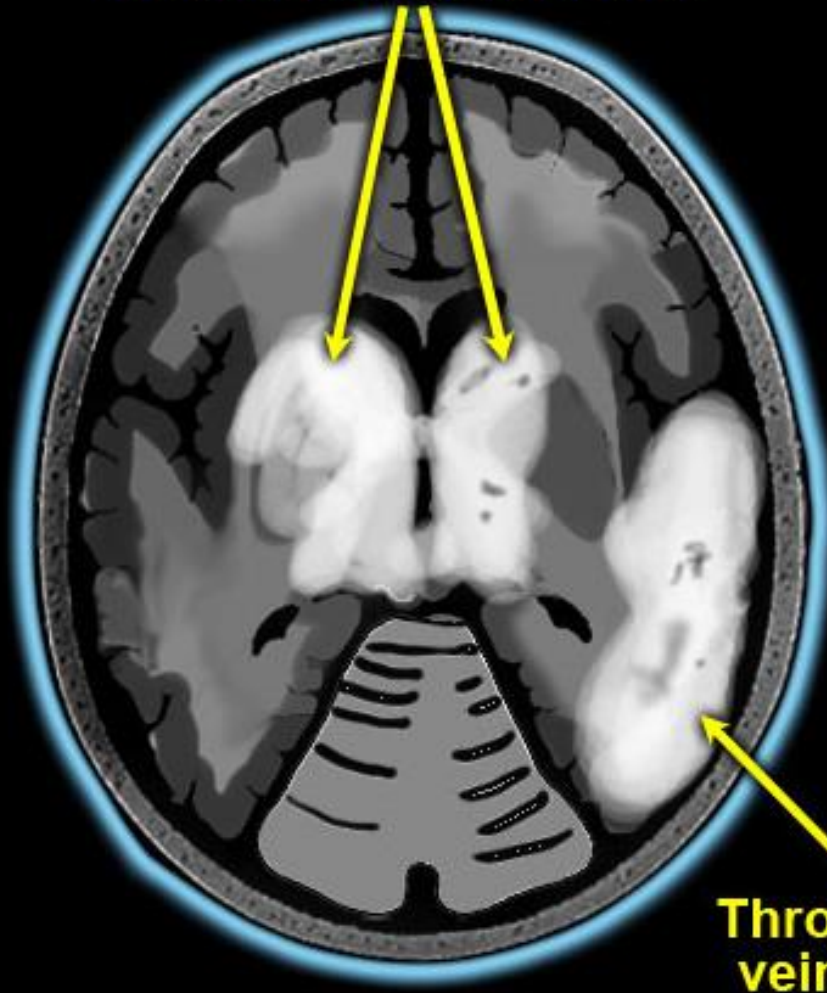
Great variation in the territories of venous drainage.

The illustrations on the left should be regarded as a rough guide.



**Thrombosis of
Internal Cerebral veins**

**Thrombosis of
Superior sag sinus**



**Thrombosis of
vein of Labbé**