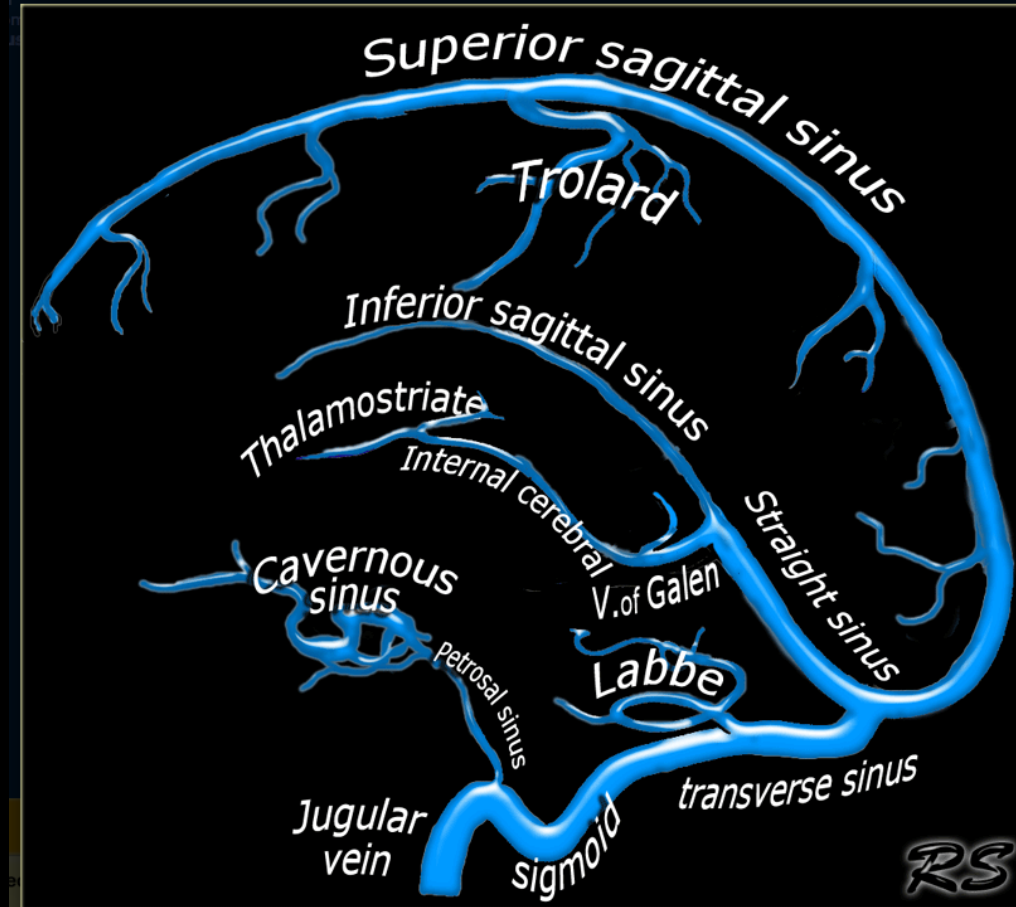


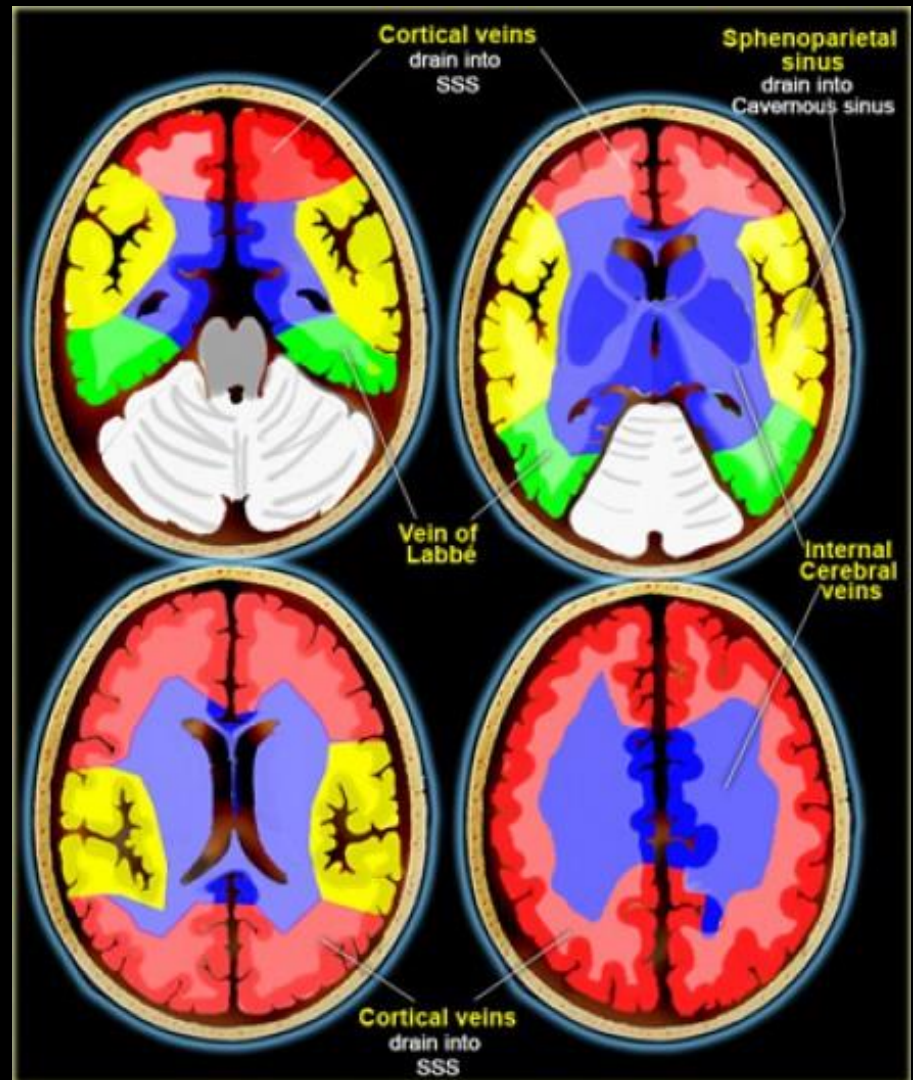
# Venous Anatomy



# CT Venography

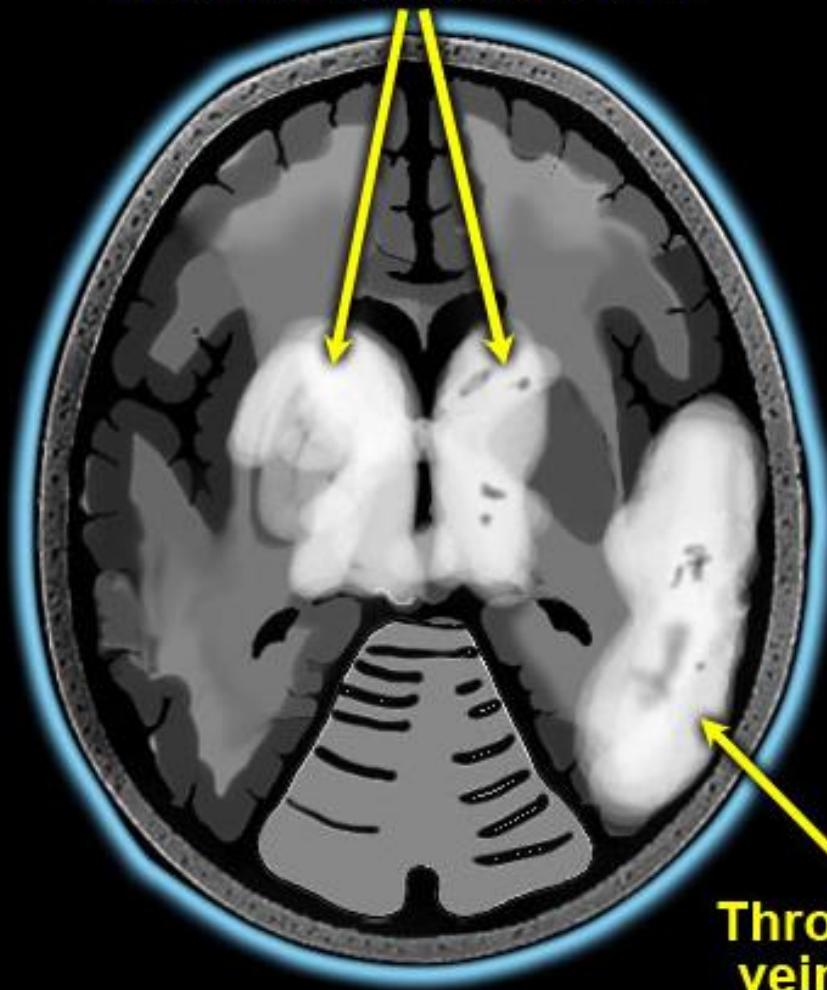
- 45-50 seconds delay after the start of contrast injection.
- We use at least 70 cc of contrast.

Great variation in the territories of venous drainage.  
The illustrations on the left should be regarded as a rough guide.



**Thrombosis of  
Internal Cerebral veins**

**Thrombosis of  
Superior sag sinus**



**Thrombosis of  
vein of Labbé**

