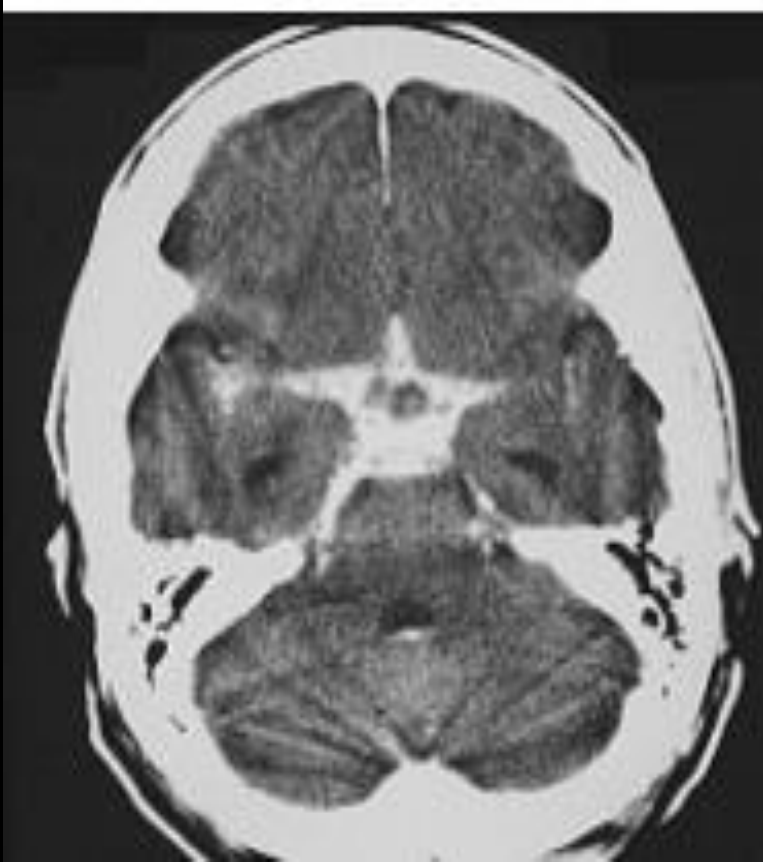
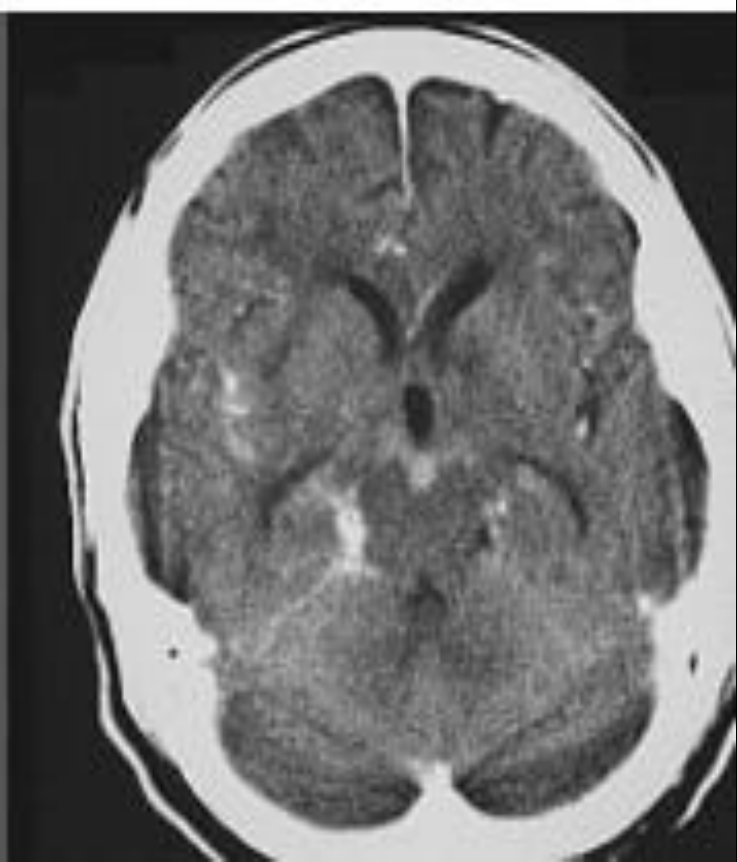


TB (post contrast)

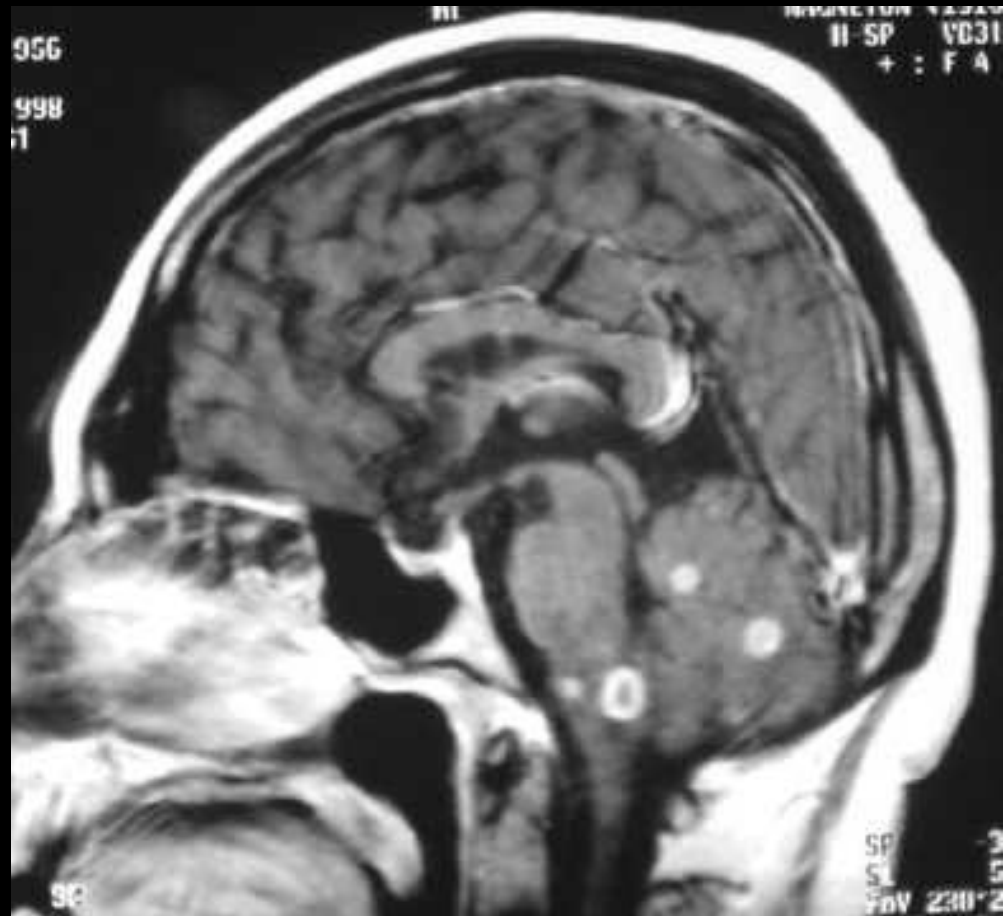
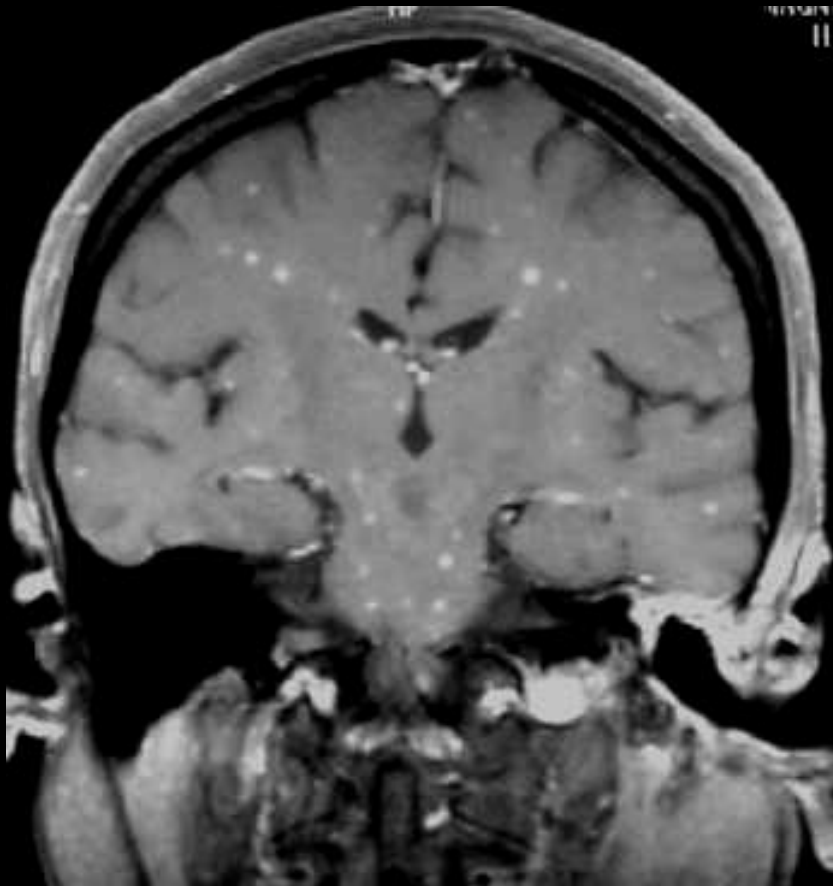


Leptomeningeal enhancement



In kids also think

Miliary tuberculosis of the brain



Tuberculosis with exudative leptomeningitis, tuberculomas, and left MCA territory infarct

